

# An Unusual Case of Isolated Spongy Right Ventricular Myocardium

Rajendra Kumar J<sup>1</sup>, Sanath Kumar T<sup>2</sup>, Venkata Rajaiah N<sup>3</sup>

<sup>1</sup>Associate Professor  
in Medicine,

<sup>2</sup>P.G. Student

<sup>3</sup>Professor

Department of Medicine,  
Chalmeda Anand Rao  
Institute of Medical Sciences,  
Bommakal, Karimnagar,  
Andhra Pradesh, INDIA

## Correspondence:

<sup>1</sup>Dr. J. Rajendra Kumar,  
MD (Medicine)

E-mail:

krarendramamta@gmail.com

## ABSTRACT

**Aim:** Here we report a case of 40 year old normotensive female patient with an isolated right ventricular non-compaction.

**Method:** This rare entity can be easily diagnosed by characteristic appearance of excessive prominent myocardial trabeculation and deep inter-trabecular recesses in the ventricular wall. The clinical manifestations include heart failure signs, ventricular arrhythmias and cardio-embolic events. Although the usual site of involvement is the left ventricle, the right ventricle (RV) can be affected.

**Conclusion:** Isolated Ventricular Non-Compaction is a rare type of cardiomyopathy resulting from arrested myocardial development during embryogenesis. Although the usual site of involvement is the left ventricle, the right ventricle (RV) can be affected.

**KEY WORDS:** Right heart failure, cardiomyopathy, LVNC, echocardiography.

## INTRODUCTION

Myocardial non-compaction is a rare disorder with uncertain etiology characterized by excessive and prominent trabeculations associated with deep recesses that communicate with the ventricular cavity but not the coronary circulation.<sup>(1)</sup> Failure of regression of trabeculations during embryogenic development is the underlying pathogenesis.<sup>(2)</sup> Non-compacted ventricular myocardium (NCVM) is a genetically heterogeneous disorder with familial and sporadic forms and linked to mutation in several genes. The disease can be presented at any age with progressive ventricular dysfunction and increased incidence of thrombo embolism and arrhythmias.<sup>(3)</sup> This condition can be diagnosed very easily by non-invasive diagnostic procedure like echocardiography and magnetic resonance imaging (MRI).

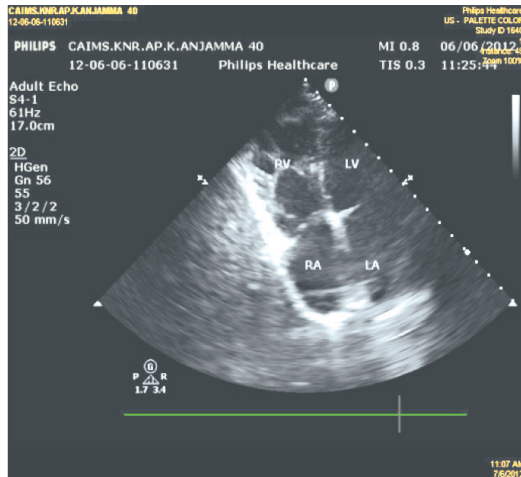
## CASE REPORT

A 40 year old normotensive female came with the history of exertional dyspnea for past 6 months. She had a history of facial puffiness and pedal edema and also had exertional palpitation. On examination she was a febrile with pulse rate 98/minute, regular, blood pressure 120/70 mmHg and respiratory rate 18/minute. There was pallor and bilateral edema over lower extremities. She had elevated jugular venous pressure (7cm above sternal angle) with a prominent

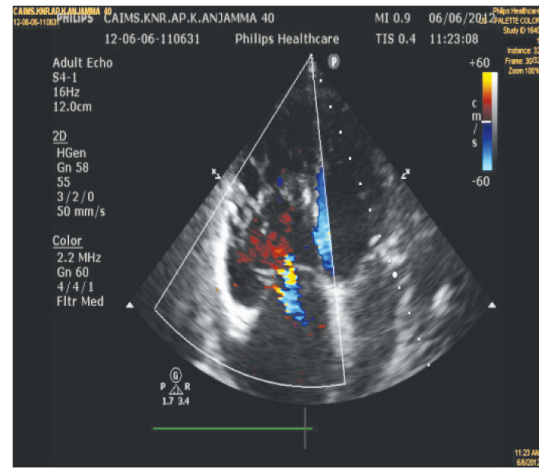
“y” descent. There was no cyanosis, clubbing, icterus and lymphadenopathy. On cardiovascular examination there was loud P2, grade 3/6 systolic murmur in tricuspid region. Respiratory system examination revealed normal findings. Chest X-Ray demonstrated cardiomegaly with normal pulmonary vasculature. Surface electrocardiogram was normal. Transthoracic 2D echocardiogram revealed enlarged right heart chambers with spongy (or honeycomb) appearance in apical, mid cavity and free wall of right ventricle. Colour Doppler demonstrated flow from right ventricular cavity into the deep intertrabecular recesses and moderate tricuspid regurgitation. Left ventricle was normal. On the basis of Transthoracic 2D echocardiography she was diagnosed as an isolated non-compacted right ventricular myocardium.

## DISCUSSION

Myocardial non-compaction is a rare disorder with uncertain aetiology. According to the report of World Health Organization/International Society and federation of cardiology Task Force in 1995, non-compacted ventricular myocardium (NCVM) is categorized as an “Unclassified Cardiomyopathy”. Normally during 5 to 8 weeks of gestational, inter-trabecular spaces are obliterated and ventricular compaction occur from the base of heart toward the apex and from epicardium to endocardium and an arrest



**Figure 1:** Trans thoracic echocardiogram in apical 4 chamber view showing trabeculations and deep intertrabecular recesses prominent at the apex, mid cavity and free wall of right ventricle (RV- Right ventricle, RA- Right atrium, LV- Left ventricle, LA- Left atrium).



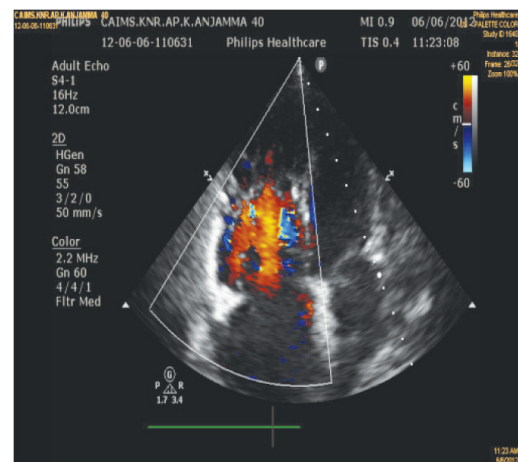
**Figure 2:** Trans thoracic echocardiogram in apical 4 chamber view showing dilated right ventricle, right atrium and prominent deep intertrabecular recesses and trabeculation at the RV apex, mid cavity and free wall.

in progression of ventricular compaction result in non-compaction. However the exact etiology still remains unknown. The usual site of involvement is left ventricle and very rarely isolated right ventricular non-compaction can be seen. Both familial and sporadic forms of NCVM have been described. NCVM is more common in male (male to female ratio is 5.5:1).

The following diagnostic criteria of NCVM have been defined on basis of echocardiography are <sup>(1)</sup> A two layered structure of the ventricular wall with end systolic ratio on non-compacted to compacted myocardial layer >2. <sup>(2)</sup> Predominant area of involvement are apical and mid ventricular. <sup>(3)</sup> The blood flow directly from the ventricular cavity into deep inter-trabecular recesses as assessed by color Doppler echocardiography. <sup>(4)</sup> The absence of coexisting cardiac anomalies.

In our patient, all four echocardiography criteria of NCVM were present. Trans thoracic echocardiography (TTE) is the best non-invasive tool to demonstrate ventricular trabeculations and perfused inter-trabecular recesses. NCVM can also be diagnosed by Trans esophageal echocardiography (TEE), Computed tomography and magnetic resonance imaging. In our case non-compaction was diagnosed by TTE. The major complications are heart failure, arrhythmias, sudden cardiac death and cardio-embolic events and syncope.

Our patient presented with all clinical manifestations of right heart failure. Endomyocardial morphology in NCVM is responsible for development of mural thrombi within inter-trabecular spaces. All adult patients are recommended oral anticoagulation, irrespective of ventricular size. In NCVM patient the prognosis is variable from prolong asymptomatic



**Figure 3:** Color Doppler echocardiography showing blood flow directly from the right ventricular cavity into deep inter-trabecular recesses.

course to severe cardiac disability, leading to heart transplantation and death. Approximately up to 50% of the patients died suddenly. Prognosis is worse in patient with heart failure NYHA class III –IV, LV end-diastolic diameter >60mm, the left bundle branch block and chronic atrial fibrillation, no such criteria for prognosis have been proposed for isolated right ventricular non-compaction. Our patient was treated with thiazide diuretic, digoxin, warfarin, ACE-inhibitors and aldosterone antagonist.

## REFERENCES

1. Chin TK, Perloff JK, Williams Rg, Jue K, Morhmann R. Isolated non-compaction of left ventricular myocardium: a study of eight cases. *Circulation* 1990;82:507-13.
2. Richardson P, Mckenna W, Bristow M, Maisch B, Mautner B, O'Cannel J, Oslen E, Thienne G, Goodwin J et al. Report of 1995 world health organization/International Society and federation of cardiology task Force on the definition and classification of cardiomyopathy, *Circulation* 1999;99:841-2.
3. Reynen K, Bachmann K, Singer H. Spongy myocardium. *Cardiology* 1997;88:601-2.
4. Agmon Y, Connolly HM, Olson U, Khanderia BK, Seward JB. Noncompaction of ventricular myocardium. *J. Am. Soc. Echocardiography* 1999;12:859-63.
5. Oeschlin E, Attenhofer C, Rohas J, Kauffman P, Jenni R. Long term follow up of 34 adults with isolated left ventricular noncompaction: a distinct cardiomyopathy with poor prognosis. *J Am Coll cardiol* 2000;36:493-500.
6. Ying ZQ, Xu G, Chen S, Ma J, You XD. Cerebral infarction in an adult patient with right ventricular hyper-trabeculation/noncompaction. *Int J cardiol* 2008;127:150-51.
7. Elshershari H, Okutan V, Celiker A. Isolated noncompaction of ventricular myocardium. *Cardiol Young* 2001;11:472-5.
8. Yuksel C, Necmi A, Bilgin T, Bulent G, Omer G, Gulmira K, Ahmet U. Noncompaction of ventricular myocardium: report of two cases with bicuspid aortic valve demonstrating poor prognosis and with prominent right ventricular involvement. *Echocardiography* 2003;20:279.
9. Antoniadou LC, Moustafa IA, Zambartas CA. Isolated ventricular noncompaction. *Hellenic J Cardiol* 2003;44:286-90.
10. Gomathi SB, Makadia N, Ajit SM. An unusual case of isolated noncompaction right ventricular myocardium. *European journal of Echocardiography* 2008;9:424-25.