

# Fracture Calcaneum, Open Reduction and Internal Fixation: A Prospective Study

Nagamuneendrudu K<sup>1</sup>, Ashok <sup>2</sup>, Moorthy GVS <sup>3</sup>, Rama Krishna G<sup>4</sup>

## ABSTRACT

**Aim:** Calcaneum fractures account for approximately 2% of all fractures. Most common in young, mostly working and earning age group of population, most frequently due to fall from height, less common are RTA. These fractures can be either intra-articular and extra-articular, the intra-articular variant being more common. The treatment of calcaneum fractures continues to pose a challenge. The primary disagreement is between operative and non-operative treatment. The literature suggests significant benefit from operative management of these fractures; complications have been shown to be a common problem in many studies. There are many methods of stabilization of calcaneum fractures, each having their own merits and demerits. The contoured plate fixation has improved the functional results, limited indication for bone grafting and shortened duration of treatment.

The purpose of the present study is to verify the functional outcome of the contoured plate fixation, in displaced intra-articular calcaneum fractures with reference to: 1. Operative procedure and anatomical reduction 2. Post-operative period and early mobilization 3. Final functional outcome.

**Materials and Methods:** Our study included patients reporting to Osmania General Hospital, Hyderabad from May 2010 to October 2012, treated by internal fixation using recon plates, cancellous screws and k-wires and those who were available for follow up

**Results:** Thirty patients with comminuted calcaneal fractures were operated from May 2010 till October 2012. Of the 30 patients majority are (28) male with a mean age of 37 years, and mode of injury in majority (24) of patients was fall from a height. Of the 30, 8 had excellent results, 16 had good results, 4 had fair results and 2 had poor results.

**Conclusion:** Fractures of the calcaneum are one of the common fractures, mostly involving the young and earning age group of population, and treatment modality has to be decided carefully. We are of the opinion that the operative treatment of comminuted calcaneum fractures should be done as anatomical reduction and rigid internal fixation is essential to allow early movement and weight bearing. The technique of plate fixation with a lateral approach is good with regards to fracture union and functional outcome. It also shows that anatomical reduction in terms of the restoration in Bohler's and Gissane's angle plays an important role in determining the good functional outcome.

**Keywords:** Fracture calcaneum, open reduction, internal fixation

<sup>1</sup> Associate Professor  
<sup>2</sup> Post graduate Student  
<sup>3</sup> Professor & Head  
<sup>4</sup> Tutor  
 Dept of Orthopaedics and  
 Traumatology  
 Osmania Medical College  
 Hyderabad, Andhra Pradesh,  
 India.

## CORRESPONDENCE:

Dr. K. Nagamuneendrudu,  
 MS (Ortho),  
 Associate Professor  
 Dept of Orthopaedics and  
 Traumatology  
 Osmania Medical College,  
 Hyderabad, Andhra Pradesh,  
 India.  
 E-mail:  
 knagmuni60@gmail.com

## INTRODUCTION

Calcaneum fractures account for approximately 2% of all fractures. These fractures can be classified broadly into intra-articular and extra-articular types, with the intra-

articular variant being more common, representing 70-75% of all fractures of the Calcaneum, frequently resulting from axial loading with carrying degrees of shear force.

The treatment of calcaneum fractures continues to pose

a challenge for the trauma surgeons despite advancement in surgical technique and implant devices. The primary source of disagreement has been the issue whether better results are achieved with operative or non operative treatment. Operative treatment methods include, open reduction and internal fixation, percutaneous fixation and primary arthrodesis. Historically, displaced intra-articular calcaneal fractures were treated non-operatively as surgery was not well developed. Surgery was associated with significant incidence of wound complications, particularly sepsis. However, non-operative treatment of displaced intra-articular fractures was associated with long term symptoms of pain and deformity. The surgical options were mostly salvage operations. The complications of calcaneal fractures were not satisfactorily mitigated, with limited better outcomes only in few percentage of cases.

So it is the need of the hour, to identify treatment techniques, which restores normal anatomy, normal or near normal function, and achieve better functional outcomes in terms of shorter duration of treatment, better stability, and early weight bearing, least surgery related complications.

Since early 1990s, enthusiasm for surgical procedures, for carefully selected fractures, in appropriate surgical candidates has increased. Because of its unique shape, difficulties arose in understanding the geometry of the calcaneal fractures. Because of its location, surgical treatment was fraught with complications till recently. Improvement in imaging technology has allowed a better understanding of fracture pathology and provided the basis for newer classifications, which has revolutionized the treatment of calcaneum fractures.

There remains, however, no consensus regarding the surgical approach, medial, lateral, combined medial and lateral, extended lateral and sinus tarsi approached. Further, the method of fixation remains a point of debate, with pins, screws or plate and screws fixation, with or without bone grafting. Post operative complications have been shown to be a common problem in many studies. Among many methods of stabilization of calcaneum fractures, each having their own merits and demerits. The contoured plate fixation has improved the functional results, limited indication for bone grafting and shortened duration of treatment.

The purpose of the present study is to define the criteria for surgery, verify the functional outcome of the contoured plate fixation, in displaced intra-articular

calcaneum fractures.

## MATERIALS AND METHODS

Our study included patients reporting to Osmania General Hospital, Hyderabad from May 2010 to October 2012, Adult patients with displaced calcaneal fractures, treated by internal fixation using recon plates, cancellous screws and k-wires and those who were available for follow up.

### Inclusion Criteria:

- All patients above 18 years of age with comminuted calcaneum fractures
- Fresh fractures
- Patients should be walking prior to the fracture

### Exclusion Criteria:

- Open fractures
- Pathological fractures
- Calcaneal fractures with other associated fracture in lower limb
- Fractures in children
- Fractures in adults >55 years
- Grossly comminuted fractures
- Severely osteoporotic bone

A thorough history and clinical examination was done. The swelling of the heel and status of the skin was recorded. X-rays of the calcaneum were taken on admission which included lateral and axial views. CT scans were taken to further evaluate the fracture pathology. The patient was temporarily put on a below knee slab with adequate limb elevation until the swelling subsided and there were wrinkles seen on the lateral aspect of the heel.

The fractures were classified based on the Essex-Lopresti and Sander's classification. All the fractures in our study were joint depression type with 17 patients having Sander's type II and 8 having Sander's type III fracture.

The patient was then posted for internal fixation with 3.5mm contoured recon plates, cancellous screws and k-wires whatever is appropriate. The lateral extensile approach was used for all the patients.

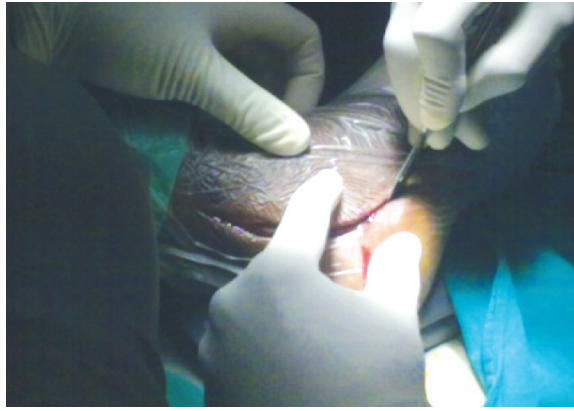

Figure:1 Incision

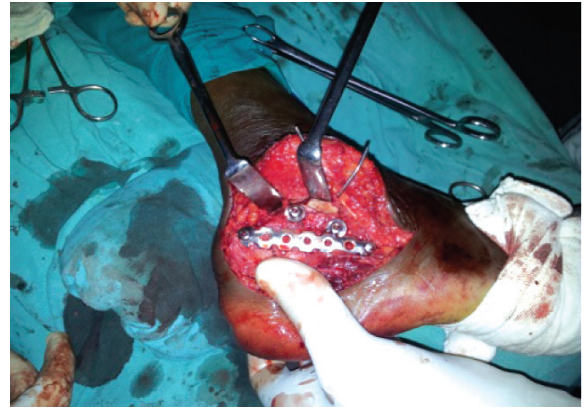


Figure: 2 Implant in situ

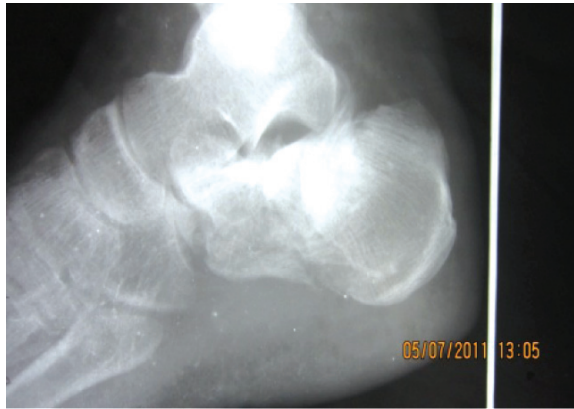

Figure: 3 Pre operative X-Ray

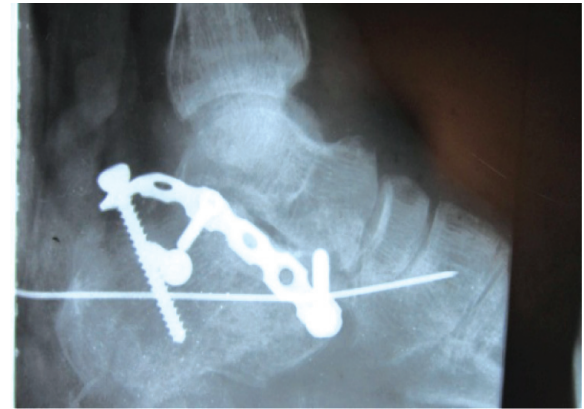


Figure: 4 Post operative X-Ray

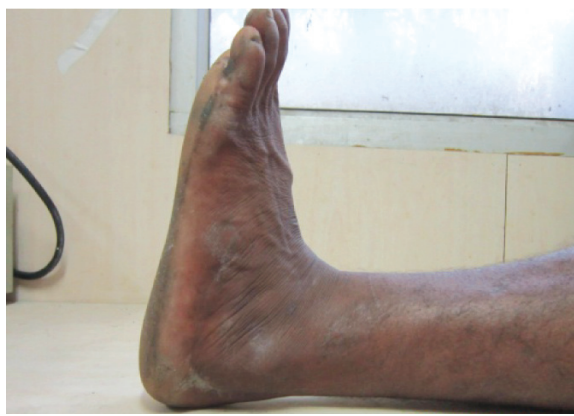

Figure:5 Post operative Dorsiflexion

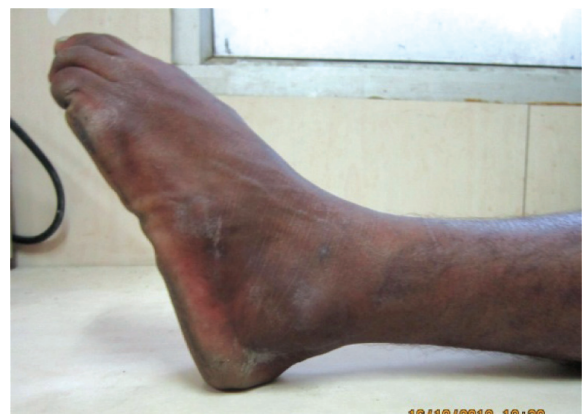

Figure:6 Post operative Plantar flexion

## FOLLOW UP AND CRITERIA FOR EVALUATION

The patients were followed up clinically and radiologically at 6 weeks, 12 weeks, 6 months, and 1 year, with respect to height of calcaneum, width of the calcaneum, range of movements at subtalar joint, tubero-talar angles. At every follow up clinical examination was done to assess status of the surgical wound, pain, tenderness, range of motion of subtalar joint, stability of the fracture and clinical union. Roentgenograms were taken in Lateral and axial views to look for signs of radiological union.

In our study we concluded clinical union when the fracture site had become stable and pain free. The union is confirmed radiologically when plain X-ray showed bone trabeculae or cortical bone crossing fracture site on at least three surfaces on orthogonal radiograms. The time taken for clinical and radiological union was noted. If there are no clinical and radiological signs of union by 16 weeks, the fracture was categorised as delayed union and in the absence of fracture union after 24 weeks after injury was categorized as non union. We had 1 case of delayed union following fixation.

The functional outcome was measured by the "American Orthopaedic Foot and Ankle Society (AOFAS) Ankle Hindfoot scoring system" at twelve months. The AOFAS scoring system is a very useful tool to measure function of the foot developed by the American Academy of Orthopaedic Surgeons (AAOS) and has been validated by various studies. The AOFAS score is a 100 point scoring system mainly assessing the pain, function and alignment of the foot. The functional outcome decreases as the score decreases.

The result was then graded as Excellent, Good, Fair and Poor as follows

Excellent - 89 to 100 Points.

Good - 79 to 89 points.

Fair - 69 to 79 points.

Poor - Less than 60 points.

## RESULTS AND DISCUSSION

There were 30 adult patients who presented with calcaneal fractures to our hospital during the course of the study. Of the 30 patients, 28 were male and 2 were females between the age group of 19-56 years (mean age 37 years)

S. No	Age Group	No. of patients
1	18-24	02
2	25-34	12
3	35-44	10
4	45-54	06

Two patients had bilateral fractures. Of the 25 patients, 18 (60%) had left sided fractures, while 12 (40%) had right sided fracture.

### Limb involved

S. No	Side Involved	No. of patients
1	Right	12
2	Left	18

The mode of injury for 24 patients was fall from height and for 6 patients was RTA. Of the 30, 18 (66.66%) had Sander's type III fracture and 10 (33.33%) had a Sander's type II fracture.

### Sanders classification

S. No	Type	No. of patients
1	Sander's II	10 (66.66%)
2	Sander's III	20 (33.33%)

Of the 30, all patients had gross swelling of the foot following the injury. The number of days from the fall to surgery varied from 2-14 days (means 6.3 days). Days of hospital stay varied from 14-22 days (means 16.04 days).

### No. of days between the fall and operative procedure

S. No	Days between fall and surgery	No. of patients
1	0-5	6
2	6-10	14
3	11-15	10

Of all 30, 29 patients were treated with a lateral extensile approach and fixed with recon plates and cancellous screws and one was treated with percutaneous k wire fixation. Post operatively 6 (32%) patients had persisting pain, 2 had superficial infection. Both the patients with

superficial infections were treated with injectable antibiotics for a week and oral antibiotics for another week. Suture removal was delayed till the wound infection subsided and patients were discharged. Further follow-up showed no signs of any infection. The one patient with deep infection was treated repeatedly with a course of injectables and oral antibiotics.

**Post operative complications**

S. No	Post operative complications	No. of patients
1	Persistent pain	6
2	Swelling	14
3	Superficial infection	02
4	Deep infection	01

Mean number of days of hospital stay was 16.

All the operated patients showed an increase in the Bohler’s angle and decrease in the gissane’s angle with statistically significant p value. Post operatively all patients had an increase in heel height and decrease in heel width with a statistically significant p value.

At 12 weeks of follow up, x rays of 27 patients showed radiological signs of union. Mean duration of radiological union was 12.5 weeks with SO of 1.79. Three patients had delayed union radiologically

**Results as per AOFAS scoring**

Results	Excellent	Good	Fair	Poor
	8	16	4	2

Of the 30, 8 had excellent results, 16 had good results, 4 had fair results and 2 had poor results.

The mean ROM of subtalar and ankle joints of patients with excellent results are as follows. Inversion and eversion are 23.66 and 18.90degrees respectively, and the mean dorsiflexion and plantarflexion of ankle are 30 and 25 degrees respectively.

The mean ROM of subtalar and ankle joints of patients with good results are as follows. Inversion and eversion are 20.28 and 15.34 degrees respectively, and the mean dorsiflexion and plantarflexion of ankle joints are 25 and 20 degrees respectively.

The mean ROM of subtalar and ankle joints of patients with fair results are as follows. Inversion and eversion are 16.42 and 12.85 degrees respectively, and the mean dorsiflexion and plantarflexion of ankle are 20 and 15

degrees respectively. The mean ROM of subtalar and ankle joints of patients with poor results are as follows. Inversion and eversion are 10 and 7.5 degrees respectively, and the mean dorsiflexion and plantar flexion of ankle are 15 degrees each.

The calcaneum is the most commonly fractured tarsal bone. The prognosis for an extra-articular fracture is uniformly good, but that for an intra-articular fracture is very varied. There are any systems for classifying displaced intra-articular fractures, but there is no consensus amongs surgeons as to which is the most practical one. Although some studies with more than 100 cases have demonstrated good results after open reduction and internal fixation of intra-articular calcaneal fractures, the best choice of treatment remains controversial because prospective randomized studies have not shown convincingly better results after surgery. However, in the largest prospective randomized trial described to date, Buckley et al. found better results in some subgroups of patients after surgery.

It is difficult to compare outcome between studies since different measures of outcome are often used and there is no consensus among surgeons as to which is the most scientific and practical system. Essex-Lopressti, Rowe and Sanders are the commonly used classification systems for calcaneal fractures. There is varying degrees of agreement among users of these classification systems. Although, classifications show positive correlation with outcome, there is no correlation with choice of treatment. In our study we have used the Essex-Lopressti and Sander's classification systems.

Historic cohort studies have suggested equal clinical outcomes with operative and conservative treatment of displaced intra-articular calcaneal fractures. However, conservative treatment is not without its complications of subtalar joint pain, heel varus and peroneal tendon impingement. Many studies have shown superior results with operative treatment. Earlier, surgical treatment was associated with significant incidence of wound complications, particularly sepsis. We believe that displaced intra-articular fractures of the calcaneum should be treated on the same principles as any other injury of the weight bearing joint; that is by anatomical reduction and rigid internal fixation, to allow early movement and get a better functional outcome. Application of these principles to intra- articular calcaneal fracture have been difficult because of complex bony and fracture anatomy, thin soft tissue envelope and difficulty of achieving anatomic reduction and rigid fixation. Improvements that have occurred in surgical techniques and decreased complication rates have made many surgeons to opt operative treatment of these fractures.

Calcaneal fracture surgery can be performed using medial, lateral or combined approach. The lateral approach is the most popular approach. A lateral extensile exposure popularized by Benirschke and Sangeorzan was used in all our cases. Various fixation devices like pelvic reconstruction plates, calcaneal plates, K-wires or a combination of K-wires and screws can be used for fixing these fracture. We used a 3.5 mm reconstruction plate contoured to the lateral wall of the calcaneum and screws to fix these fractures. The "blow out" of the lateral wall, when present, could be well reduced and held in place with this plate. The contoured plate was fixed extending from anterior process into the most posterior aspect of the tuberosity.

In our analysis, we confirmed correlation between the Bohler's angle size and patient satisfaction in terms of their functional outcome. This fact, proved and verified by a lot of other authors, confirms the role of Bohler's angle and Gissane's angle size as a predictive factor for subsequent late complication.

AOFAS clinical rating system the Ankle Hind foot scale for calcaneal area is a standard scoring system for foot function evaluation. Using this standard scoring system that takes into account subjective and objective assessments enables to achieve relevant results and comparison of different patients studies. Finally one has to mention optimistic findings of Melcher who followed up patients operated by ORIF for 3 and 10 years after the surgery. In his study, subjective and objective results assessed after ten years were better than those achieved in a 3 years follow up.

In Sanders study, excellent or good results were obtained in 73% of type-II, 70% of type -III, and only 27% of type IV fractures. In our study, 79% of patients had excellent or good and 21% had fair or poor results, despite anatomical calcaneal restoration.

Complications occur regardless of the management strategy, despite managed by experienced surgeons. Complications are a cause of significant morbidity for patients. The rate of wound complications (superficial and deep infection) in this study was 16%, similar to that in many studies in the literature. In our study, one patient had developed deep infection.

In a meta-analysis published in 2000, Randle et al. stated that "there is a trend for surgically treated patients to have better outcomes; however the strength of evidence for recommending operative treatment is weak". They concluded that before a strong recommendation could be made for operative treatment, a randomized trial with controls and validated outcomes was needed.

There were certain limitations to our study. Only 30

patients with calcaneal fractures were operated and their functional outcomes scores were measured at a mean follow up of 12 months. A study involving more patients followed up for a longer period of time can more accurately define the functional outcome of calcaneal fractures treated by this method. Therefore this study is essentially a preliminary assessment.

## CONCLUSION

Thirty patients with comminuted calcaneal fractures were operated from May 2010 till October 2012. Of the 30 patients majority (28) male, the mean age of 37 years, mostly unilateral, 18 had left sided fractures while 12 had right sided fractures and mode of injury, in majority of cases was fall from a height and RTA in minority. 20 patients had Sanders type 3 fracture and 10 patients had Sanders type 2 fractures. Days of hospital stay varied from 14 to 22 days [mean 16.04 days]. Of the 30 patients, 8 had excellent results, 16 had good results, 4 had fair results, 2 had poor results, comparable to the study of Sanders. Hence we concluded from the above findings the internal fixation helps in improving the functional outcome of the patients in view of their physical and radiological findings, this study is essentially a preliminary assessment, needs further study with large group of patients and longer follow up.

## REFERENCES

1. Leung KS, Yuen KM and Chan WS, Operative treatment of displaced intra-articular fractures of calcaneum: medium term result. *Journal of bone and joint surgery* 1993; 75:196-201
2. Monsey RD, Levine BP, Trevino SG. Operative treatment of acute displaced intra-articular calcaneum fractures. *Foot ankle int.* November 1996; 17: 2-9.
3. Laughin RT, Carson JG and Calhoun JH. Displaced intra-articular calcaneum fractures treated with the Galveston plate. *Foot ankle int.* 1996; 17: 71-78.
4. Tometta P. Open reduction internal fixation of calcaneum using minifragment plates. *Journal of orthopaedic trauma.* 1996; 10: 63-67.
5. V. Sharma, R Shahid and M. Masqood. Early results of calcaneal locking plate for displaced intra-articular calcaneal fractures. *Injury extra.* May 2008; 39 issue 5:183.
6. Rak V, Ira D, Masek M. Operative treatment of intra-articular calcaneal fractures with calcaneal plates and its complications. *Indian journal of orthopaedics.* 2009; 43: 271-280.
7. Benirschke SK, Sangeorzan BJ. Extensive intra-articular fractures of the foot: Surgical management of calcaneal fractures. *Clin Orthop.* 1993; 292: 128-34.
8. Melcher, Gian, Degonda, Frena, Leutenegger, Adrian, Ruedi, Thomas. Ten Year Follow-up after Operative Treatment for Intra-articular Fractures of the Calcaneus. *Journal of Trauma-Injury Infection & Critical Care:* May 1995; 38 issue 5: 713-716
9. Sanders R, Fortin P, DiPasquale T, Walling A. Operative treatment

- in 120 displaced intraarticular calcaneal fractures. Results using a prognostic computed tomography scan classification. *Clin Orthop Relat Res.* 1993 May;(290):87-95.
10. Zwipp, Hans, Tscherne, Harald, Thermann, Hajo, Weber, Theresa . Osteosynthesis of Displaced Intraarticular Fractures of the Calcaneus Results in 123 Cases. *Clin Orthop* 1993;290:76-86.
  11. Zeman P, Zeman J, Matejka J, Koudela K. Long-term results of calcaneal fracture treatment by open reduction and internal fixation using a calcaneal locking compression plate from an extended lateral approach. *Acta Chir Orthop Traumatol Cech.* 2008 Dec;75(6):457-64.
  12. V Jain, R Kumar, DK Mandal. Osteosynthesis for intra-articular calcaneal fractures. *Journal of Orthopaedic Surgery* 2007;15(2):144-8
  13. Monsey RD, Levine BP, Trevino SG, Kristiansen TK . Operative treatment of acute displaced intra-articular calcaneus fractures. *Foot Ankle Int.* 1995
  14. Huang, Peng-Ju , Huang, Hsuan-Ti , Chen, Tai-Bin , Chen, Jian-Chih , Lin, YennKo, Cheng, Yuh-Min , Lin, Sen-Yuen. Open Reduction and Internal Fixation of Displaced Intra-articular Fractures of the Calcaneus. *Journal of Trauma-Injury Infection & Critical Care:* May 2002;52(5):946-950.
  15. M. Paul, R. Peter, P. Hoffmeyer. Fractures of the calcaneum- a review of 70 patients. *J Bone Joint Surg fBr}* 2004;86-B: 1142-5.
  16. DPaley, HHall. Intra-articular fractures of the calcaneus. A critical analysis of results and prognostic factors. *J Bone Joint Surg Am.* 1993;75:342-354.
  17. Herscovici D Jr, Widmaier J, Scaduto JM, Sanders RW, Walling A. Operative treatment of calcaneal fractures in elderly patients. *J Bone Joint Surg Am.* 2005;87: 1260-4.
  18. T. Ibrahim, M. Rowsell, W. Rennie, A.R. Brown, G.J.S. Taylor, P.J. Gregg. Displaced intra-articular calcaneal fractures: 15- Year follow-up of a randomised controlled trial of conservative versus operative treatment. *Injury July* 2007;38: (7); 848-855
  19. Trevor Gaskill, Karl Schweitzer, James Nunley. Comparison of Surgical Outcomes of Intra-Articular Calcaneal Fractures by Age. *J Bone Joint Surg Am.* 2010; 92:2884-9
  20. Jean-Luc Besse, J.P. Avaro, F. Chotel, J.L. Lerat, B. Moyen. Calcaneal intraarticular fracture osteosynthesis: Clinical and radiological prospective study of 31 cases. *Foot and Ankle Surgery* Dec 2006; 19-27
  21. Thordarson DB, Krieger LE. Operative vs. non operative treatment of intraarticular fractures of the calcaneus: a prospective randomized trial. *Foot Ankle Int.* 1996; 17:2-9.
  22. Thermann H, Krettek C, Hu"fner T, Schrott HE, Albrecht K, Tscherne H, et al. Management of calcaneal fractures in adults. Conservative versus operative treatment. *Clin Orthop* 1998;353: 107-24.
  23. D. Makki, H. M. Alnajjar, S. Walkay, U. Ramkumar, A. J. Watson, P. W. Allen. Osteosynthesis of displaced intra-articular fractures of the calcaneum- a long-term review of 47 cases. *Journal of Bone and Joint Surgery(Br);*92-B(5); 693-700
  24. Parmar HV, Triffitt PD, Gregg PJ. Intra-articular fractures of the calcaneum treated operatively or conservatively. A prospective study. *J Bone Joint Surg Br.*
  25. Bhattacharya R, Vassan UT, Finn P, Port A. Sanders classification of fractures of the os calcis. An analysis of inter- and intra-observer variability. *JBJS(B).* 2005;87(2): 205-8.
  26. Randle JA, Kreder HJ, Stephen D, Williams J, Laglal S, Hu R. Should calcaneal fractures be treated surgically? A Metaanalysis. *Clin Orthop* 2000;377-217.
  27. Bridgman Sa, Dunn Krn, Mcbride DJ, Richards Pl. Interventions for treating calcaneal fractures. *Cochrane Database Sys Rev.* 2000. CD001: 161.
  28. Sanders R. Intra-articular fractures of the calcaneus: present state of the art. *J Orthop Trauma.* 1992; 6: 252-65.
  29. Sanders R. Displaced intra-articular fractures of the calcaneus. *JBJS(A).* 2000; 82: 225-50.
  30. Myerson M, Quill GE. Late complications of fractures of the calcaneus. *IBJS (A).* 1993; 75(3):z31-41.
  31. Muller ME, Allgower M, Schneider R. *Manual of Internal Fixation. Techniques recommended by AO Group.* 2nd edition. New York:Springer;979. P. 71-87.
  32. Barei DP, Bellabarba C, Sangeorzan BJ, Benirschke SK. Fracture of the Calcaneus. *OCNA.* 2002; 33 (I): 263-85.
  33. Palmer 1. The mechanism and treatment of fractures of the calcaneus. Open reduction with the use of cancellous grafts. *JBJS(A).* 1948; 30:2-8.
  34. Letoumel E. Open reduction and internal fixation of calcaneus fractures. In Spiegel PG (editors). *Topics in Orthopaedic Trauma.* Baltimore: University Park Press; 1984. P. 173-92.
  35. Stephenson JR. Surgical treatment of displaced intra-articular fractures of the calcaneus: a combined lateral and medial approach. *OCNA.*1993; 290: 68-75.
  36. Rowe CR, Sakellarides HT, Freeman P A and Sorbic C. Fracture of the os calcis: a long term follow up study of 416 patients. *J AMA.* 1963; 184: 920.
  37. Folk JW, Starr AJ, Early JS. Early wound complications of operative treatment of calcaneus fractures: analysis of 190 fractures. *J Orthop Trauma.* 1999; 13 :369-72.
  38. Buckholz RW, Heckman JD, Court-Brown CM, Koval KJ, Tometta P, Wirth MA. *Rockwood and Green's Fractures In Adults, Vol 2, 6th Edition,* Lippincott Williams and Wilkins, 2006.
  39. Pozo JL, Kirwan EO, Jackson AM. The longterm results of conservative management of severely displaced fractures of the calcaneus. *J BJS(B).* 1984; 66: 386-90.
  40. Essex-Lopresti P. The mechanism, reduction, technique and results in fractures of os calcis. *Br J Surg.* 1952; 39: 395-419.